



**PATIENT**

Pita Walker

**SPECIES**

Canine

**BREED**

Chihuahua Mix

**SEX**

Female Spayed

**AGE**

2.14.16

**WEIGHT**

7.8lbs

**INTERPRETED BY**

Maggie Machen Lamy,  
DVM, DACVIM  
(Cardiology)

**HOSPITAL NAME**

Animal Emergency  
Hospital

**REFERRING VET**

Dr. Jones

**INVOICE**

28791

**DATE**

2.6.23

**PRESENTING CLINICAL SIGNS**

History: Cough on/off, also some skin issues, treated as allergies over the years. CXR 2 wks ago showed L side heart enlargement, tx for bronchitis. Hydrocodone made her heart pound, did not sedate or help with cough Terbutaline + Clavamox x 7d, some improvement Today cough, spit up phlegm and trouble breathing Cardio appt in Towson scheduled in 3 wks.

-Pertinent abnormal PE/Chem/CBC/UA Results: See attached.

-Current medications: Pimobendan, Furosemide.

-Sedation used: Not required to complete full diagnostic ultrasound.

-Pertinent previous ultrasound results: No previous.

-STAT: Not requested

-Imaging performed by: Andi Parkinson, BS, RDMS.

**ECHOCARDIOGRAM FINDINGS**

2D, m-mode and Doppler imaging are available. Diffuse thickening of mitral valve leaflets (anterior > posterior) with prolapse into the left atrial lumen. Severe eccentric mitral regurgitation with severe left atrial dilation. Significant LV dilation with hyperdynamic myocardial function. The tricuspid valve appears mildly thickened, with no tricuspid regurgitation. Mild right atrial and ventricular dilation consistent with early pulmonary arterial hypertension. The pulmonic and aortic valves are normal in morphology and mobility. Normal pulmonic and aortic outflow velocities. No pulmonic or aortic insufficiency. No pericardial or pleural effusion noted. No cardiac tumors observed.

**CARDIAC CHART**

CANINE CARDIAC PARAMETERS	MR VMAX (m/s)	TR VMAX (m/s)	LA/AO (Boon method)	LA/AO (Heart Base; Swe)	FS (%)	EF (%)	EPSS (cm)
NORMAL PARAMETER	4.5-5.5	<2.7	1.3	<1.6	28-40	40-100	<0.6
PATIENT	5.5	NA	NM	2.0	54	86	NM
CANINE CARDIAC PARAMETERS	HR (BPM)	AV VMAX (m/s)	PV MAX (m/s)	BODY WEIGHT (kg)	LA 2D short axis Base view (cm)	LVIDd Avg; 2D and m-mode short axis (cm)	LVIDs Avg; 2D and m-mode short axis (cm)
NORMAL PARAMETER	50-100	0.7-1.7	0.7-1.6	BELOW	BELOW	BELOW	BELOW
PATIENT	200	0.95	0.9	3.5	2.3	2.9	1.4
*Normal chamber parameters expressed as a mean value (SD)				3	1.27 (5.3)	2.46 (2.46)	1.36 (5.5)
BODY WEIGHT DEPENDENT PARAMETERS				5	1.40 (4.5)	2.74 (5.2)	1.60 (4.7)
<i>*Note: All measurements based upon multi-modal images and methods. An average value is reported.</i>				10	1.50 (3.8)	3.27 (3.5)	2.06 (3.1)
				15	1.83 (2.0)	3.71 (2.4)	2.43 (2.1)
				20	2.02 (1.9)	4.14 (2.2)	2.80 (2.0)
				25	2.18 (2.4)	4.48 (2.9)	3.10 (2.5)
				30	2.33 (3.3)	4.83 (3.9)	3.39 (3.4)
				35	2.48 (4.3)	5.17 (5.0)	3.69 (4.5)
				40	2.62 (5.2)	5.48 (6.1)	3.96 (5.4)
				50	2.88 (7.1)	6.07 (8.3)	4.46 (7.4)

Adapted from June Boon, Veterinary Echocardiography, 1998  
Rishniw M and Hollis NE, J Vet Intern Med 2000; 14:429-435  
Hansson et al, Vet Rad and Ultrasound 2002  
Bonagura et al. Echocardiography: principles of interpretation, Vet Clin North Am 15:1177, 1995

## INTERPRETATION OF THE FINDINGS & FURTHER RECOMMENDATIONS

The cause of the murmur is chronic degenerative valve disease causing severe mitral regurgitation. Severe left atrial enlargement indicates the risk for spontaneous congestive heart failure is elevated. No additional issues such as systolic dysfunction are identified.

The described cough is likely multi-factorial in origin, including a mechanical component due to cardiomegaly, possible concurrent airway disease and/or early CHF given the severity of disease. Screening chest radiographs do not mention CHF; however, given the severity of disease seen here, full lifelong cardiac support is recommended as below including Lasix therapy. Depending on clinical response to the medications, cough suppression may also be useful. Monitoring of sleeping breathing rates in the future will be paramount to determine the origin of any future cough. The average survival of canine patients with active pulmonary edema is 8-9 months on medications, however they generally are able to maintain a good quality of life for that period. Patient will always be at risk for recurrent CHF, development of arrhythmias/LA tear, syncope and/or sudden death in the future. Monitoring of renal values is recommended lifelong.

Omega fatty acid supplementation and mild salt restriction may also be of some long term benefit. Monitor for development of a worsening cough, labored breathing, exercise intolerance or collapse episodes.

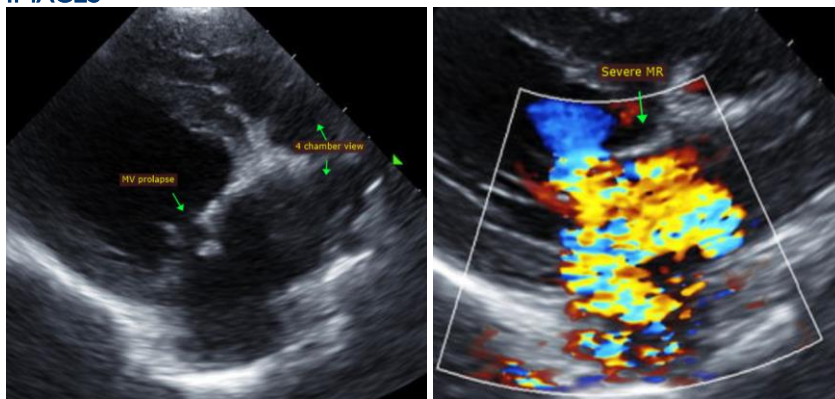
## PLAN

Screening BP is recommended. Continue Pimobendan 0.3mg/kg PO q12h. Continue furosemide/Lasix 1 mg/kg PO q12h. Administer spironolactone 1-2mg/kg PO q12h. Consider hydrocodone with homatropine (0.2-0.4mg/kg PO up to q4-6 hours PRN) if cough persists despite normal SRRs.

A renal panel and BP are recommended in 10-14 days, then every 3-4 months on diuretics to ensure tolerance of medications. If doing well at that time and BP >130mmHg, institute ACEI 0.5mg/kg PO q12h.

A recheck echocardiogram is recommended in 6 months to screen for progression, sooner if clinical signs arise/persist.

## IMAGES



The information and recommendations provided are based on the images presented by the referring veterinarian. No evaluation can be communicated regarding pathology that was not visible in the image/video clips provided.

Thank you for this referral. This report was generated using transcription software, and minor dictation errors may be present. If the clinical or image interpretation does not parallel your findings or if I can be of any further assistance please contact me.

**Maggie Machen Lamy, DVM**  
**Diplomate of the American College of Veterinary Internal Medicine (Cardiology)**  
**info@sonopath.com**